SNOMED CT incl. Postcoordination in Pathology


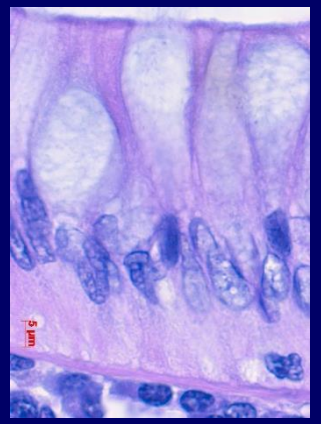
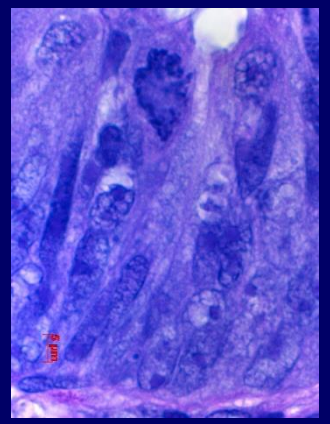
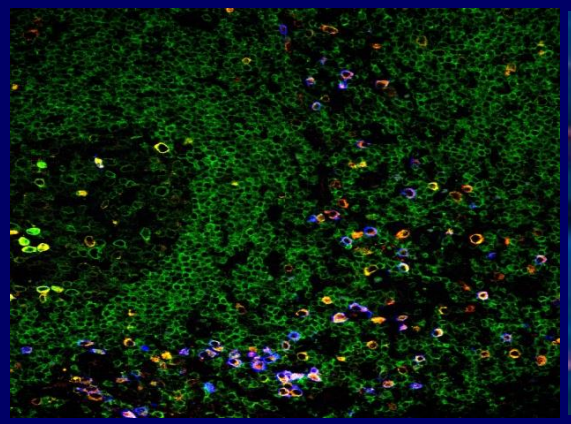
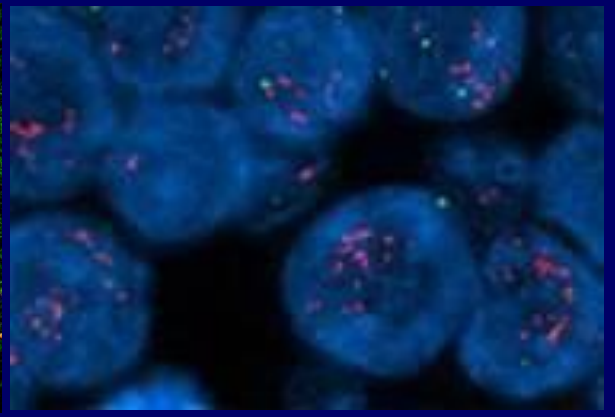


Thomas Rüdiger, Städtisches Klinikum Karlsruhe



- Snomed CT Implementation Course
- Snomed CT Authoring Course Level 1 and 2
- Lead Snomed CT Pathology and Laboratory Medicine Clinical Reference Group

- ICCR Pathology Synoptic Report Implementation Group
- Medizininformatikinitiative Kerndatensatzteam Pathologie

Specimen

Pathology

Report

Pathologen sind Lotsen der Therapie.
Pathologists guide therapuetic decisions.

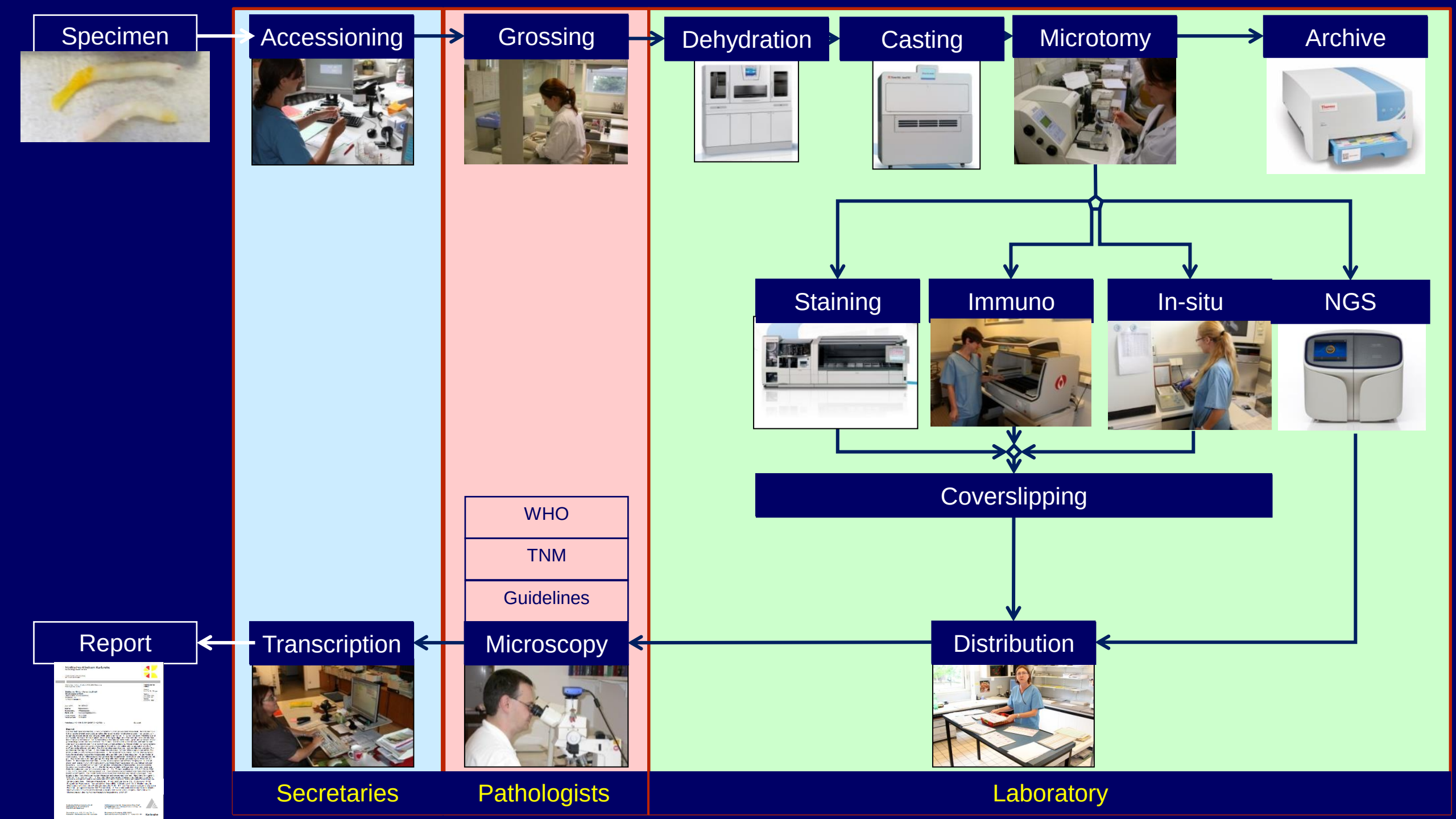
Specimen
Accessioning
Grossing
Dehydration
Casting
Microtomy
Archive
Staining
Immuno
In-situ
NGS
Coverslipping
WHO
TNM
Guidelines
Report
Transcription
Microscopy
Distribution
Secretaries
Pathologists
Laboratory

Motivation

- 10 Pathologists

Autopsies	50
Histology cases	43.000
Cytology cases	10.000
Immunhistochemistry	50.000
Molecular pathology	2.000

> 50.000 Diagnoses = Decisions
- 20% about cancer

Codable Observations



Standardization
- Intra-observer reliability
- Inter-observer reliability
- Comprehensibility

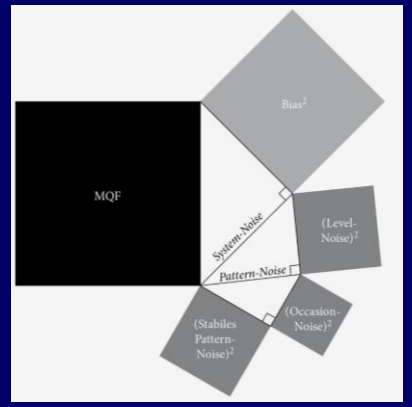

Specimen

Narrative report

Städtisches Klinikum Karlsruhe
Gemeinnützige Gesellschaft mbH

Akademisches Lehrkrankenhaus
der Universität Freiburg

Städtisches Klinikum, Postfach 6280, 76042 Karlsruhe
Pathologisches Institut

Pathologisches Institut

Direktor
Prof. Dr. Th. Rüdiger

Telefon
0721 974-1850
0721 974-1851
Telefax
0721 974-1859

Städtisches Klinikum Karlsruhe gGmbH
Gynäkologische Klinik
Station A411-Polizeibehörde
Moltkestr. 90
D 76133 Karlsruhe

Journal-Nr.: AH 10784/01
Name: [redacted]
Vorname: [redacted]
Geb. am: [redacted]
Eingegangen: 01.01.2001
Ausgegangen: 19.04.2001

Vorbefunde: H 34149/15; MM 32400/15; H 24783/11; (Barcode)

Material:
Ein zweifach fadenmarkiertes, 5 x 4,2 x maximal 1,8 cm großes Mammaexcisat, dem dorsal 1,5 x 0,9 cm große Skelettmuskulatur anhaftet. Nahe der ventra- len Markierung ein 1 cm großer, un– scharf begrenzter derber stumpf grau weiß gebildeter Tumor. 1. Tumor (ventraler Resektionsrand mit Tusche markiert) Mikroskopisch ein sternförmig konfigurierter Tumorknoten mit zentraler hya- liner Fibrose und Elastose. Die Tumorzellen sind relativ klein bis mittel- groß und sie haben relativ gleichförmige runde oder ovale Kerne. Die Tumor- zellen bilden kleine Nester, schmale Reihen oder auch tubuläre Drüsen mit einschichtiger Epithelauskleidung. Mitosen treten nur ganz verein– zelt auf. Es kommen einige leicht erweiterte Ductuli vor, die solide oder angedeutet cribriform– meTumorzellproliferate enthalten. Der Sicherheitsabstand zum tu- schemarkierten ventralen Re– sektionsrand beträgt 0,2 cm. 2. der Abstand nach dorsal, 0,8 cm Mikroskopisch tumorfreie Ske– lettmuskulatur und tumorfreies Fettgewebe. 3. der Abstand nach cranial, 1,9 cm Mikroskopisch tumorfreies streifig fibrosiertes Fettgewebe mit unauffälli- gen Drüsenläppchen. 4. der Abstand nach caudal, 1,8 cm Mikroskopisch tumorfreies Mammagewebe mit herdförmiger Fibrose und mit ge- ringen Adenosen, die eine geringe Epithelproliferation sowie grobscholligen Mikrokalk ent– halten. 5. der Abstand nach medial, 1,5 cm Mikroskopisch tumorfreies Fettgewebe. 6. der Ab– stand nach lateral, 1,3 cm Mikroskopisch tumorfreies Mammagewebe mit unauffälligen Drüsen– läppchen. Es handelt sich um ein 1 cm großes, mittelgradig differenziertes, tubulo-lobuläres Carcinom der rechten Mamma (1.). Die Entfernung erfolgte im Gesunden mit einem minimalen Sicherheitsabstand von 0,2 cm nach ventral (2. - 6.). Tumorklassifikation: ICD-O C 50, M-8520 3, G2, pT1b, pNx, pMx, mikroskopisch R0. Das Ergebnis der Schnellschnittuntersuchung wurde telefonisch mitgeteilt. Die Paraffinschnitte nach weiterer Aufarbeitung haben vorgelegen. Das Ergebnis des immunhistochemischen Rezeptornachweises wird in einem Nachbericht mitgeteilt. 19.04.01 N a c h b e r i c h t 1. Der immunhistochemische Nachweis der Östrogen- und Pro– gesteron-Rezeptoren mittels monoklonaler Antikörper ergab bei semiquantitativer Beurteilung fol– gende Ergebnisse: Östrogen-Rezeptoren: Immunreaktiver Score IRS 0 (Skala von 0-12) Progesteron-Rezeptoren: Immunreaktiver Score IRS 0 (Skala von 0-12) 2. Bestimmung der Wachstumsfraktion mit dem Proliferationsmarker Ki-67: 6-7 der Tumorzellen zeigen eine positive Reaktion. (ausgezählt wurden 800 Tumorzellen). 3. Der semiquantitative immunhistochemische Nachweis des HER-2 neuRezeptorstatus ergab einen Score von 0 (negativ). Damit ist keine Überexpression des HER-2 neu-Rezeptors festzustellen. 24.04.01

Städtisches Klinikum Karlsruhe gGmbH
Moltkestraße 90, 76133 Karlsruhe
www.klinikum-karlsruhe.de

Aufsichtsratsvorsitzender: Bürgermeister Klaus Stapf
Geschäftsführer: Dipl.-Betriebswirt Markus Heming, Prof. Dr. Hans-Jürgen Hennes

Sie erreichen uns mit S1, S11 und Tram 2
Haltestellen: Moltkestraße und Kußmaulstraße

Registergericht Mannheim, HRB 106805
Sparkasse Karlsruhe BLZ 660 501 01 Konto 9 001 801

Karlsruhe

2010 Structured report

Angaben zum Tumor:
Tumorstadium: ypT4b ypN3a **(TNM 8.Auflage)**
Malignitätsgrad: G3 (schlecht differenziert)
Residualtumor (nach UICC): R0

Angaben zum Mammakarzinom Links

Resektatgewicht	1000 g
Maße	210 x 160 x 80 mm
Anzahl der Tumoren	1
Anzahl der angefertigten Lamellen	21
Invasiver Tumor	
Größter Tumordurchmesser	55 mm
Tumorlokalisation:	Oberer äußerer Quadrant der Brust (C50.4)
	Links
Cranialer Sicherheitsabstand	45 mm
Caudaler Sicherheitsabstand	25 mm
Medialer Sicherheitsabstand	60 mm
Lateraler Sicherheitsabstand	50 mm
Dorsaler Sicherheitsabstand	17 mm
Histologischer Typ	Invasives duktales Karzinom (nicht weiter spezifizierter Typ) (8500/3)
Malignitätsgrad (nach Elston und Ellis)	G3 (schlecht differenziert)
Score nach Elston und Ellis:	3 (Histologie)+ 3 (Kerngrading) +3 (Mitosen) = 9 (3 - 9)
Tumorstadium	ypT4b **(TNM 8.Auflage)**
Lymphknotenstatus	ypN3a (15 / 22) **(TNM 8.Auflage)**
Metastasen/Untersuchte LK Level I + II	(15 /22)
Kapselüberschreitung	Ja
Größter Durchmesser einer LK-Metastase	38 mm
Größe der Fibrosezone (im Segment,bei PST)	20 mm
Regression im LK (bei PST)	nein
Lymphgefäßeinbruch peritumoral	L 1
Veneneinbruch	V 0
Perineurales Karzinomwachstum	Pn 0
Regressionsgrad nach Sinn	Grad 1 (leichte Regression)_Tumorsklerose mit Entzündung + zytopathischen Effekten
Relevanter Mikrokalk	Nein
Resektionsrand (S3 Leitlinie 2012)	R0 (CRM > 1 mm)
Residualtumor (invasiver Tumor, nach UICC)	R0
Rezeptorstatus	
Östrogenrezeptor:	1
Progesteronrezeptor:	1
Her2-Neu Status:	1 (negativ)
Proliferation	98 %

Die Tumorerkrankung wird gemäß Landeskrebsregistergesetz an die Vertrauensstelle Baden-Württemberg gemeldet.

Standardized report

Reporting Protocol - P22.000000

Clinical Information - P22.000000

Macroscopic Report - P22.000000

Microscopic Report - P22.000000

Form controls

Invasive neoplasia (primary tumour)
- (●) Present
- ( ) Not detected

In situ neoplasia
- (●) Present
- ( ) Not detected

Neoadjuvant therapy performed?
- ( ) Yes
- (●) No

[ ] Metastasis only (no primary tumour detected)

Click here to assess additional tumour separately

Primary tumour or metastasis?
- ( ) Primary tumour
- ( ) Metastasis

Click here to assess additional tumour separately

Invasive neoplasia
- ( ) Infiltrating duct carcinoma
- ( ) Invasive lobular carcinoma
- ( ) Invasive carcinoma with ductal and lobular features ('mixed type carcinoma')
- ( ) No invasive neoplasia
- ( ) No malignant neoplasia (neither invasive nor in situ)
- ( ) Other

Click here to assess additional tumour separately

In situ neoplasia
- [ ] Ductal carcinoma in situ (DCIS)
- [ ] Classical lobular carcinoma in situ (LCIS)
- [ ] Pleomorphic lobular carcinoma in situ (LCIS)
- [ ] Florid lobular carcinoma in situ (LCIS)
- [ ] Encapsulated papillary carcinoma
- [ ] Solid papillary carcinoma in situ
- [ ] Paget disease of the nipple
- [ ] Mixed
- [ ] Other
- [ ] No in situ neoplasia

Lymph Nodes - P22.000000

Lymph node laterality
- ( ) Left
- ( ) Right
- ( ) Not specified
- ( ) No nodes submitted or found

Lymph nodes

Refers to ipsilateral lymph nodes (for contralateral lymph nodes select 'Contralateral or other non-regional lymph nodes').

- [ ] Axillary*
- [ ] Intramammary**
- [ ] Infraclavicular (subclavicular)

Other regional lymph nodes

Report



Städtisches Klinikum Karlsruhe

UNIVERSITÄT DUISBURG ESSEN
Offen im Denken

Deutsche Krebshilfe
HELFEN. FORSCHEN. INFORMIEREN.

Von der Pathologie zum Patienten:
Optimierung von Wissenstransfer und Verstehenssicherung in der Onkologie zur Verbesserung der Patientensicherheit

Prof. Dr. Martin Bentz
Prof. Dr. M. Schön
Prof. Dr. Thomas Rüdiger
Dr. Juliana Anabell Gruden
(Städt. Klinikum Karlsruhe)

Prof. Dr. Wolfgang Imo
Lisa Korte M.A.
Georgios Coussios M.A.
(Universität Duisburg-Essen)

- Calculation of derived values
- Validation
  - Completeness
  - Consistency
- Computer assisted encoding
  - ICD10, ICD-O
  - Snomed CT

Snomed CT

Different Records of a Game of Chess

Descriptive record of what happened?

To start with white moved the queen's pawn to forward two spaces. Black responded by moving a knight in front of the kings bishop's pawn. White advanced the queen's bishops pawn two spaces. Black then moved the king's-knight's pawn two spaces.

…

[47 more moves in same style]

…

Then black moved his king next to his rook.

What should white do next?

Different Records of a Game of Chess

Formal process record of what happened?

1. d4 Nf6
2. c4 g6
3. Nc3 Bg7
4. e4 d6
5. Be2 e5
6. dxe5 dxe5
7. Qxd8 Kxd8
8. f4 Nfd7
9. Nf3 c6
10. O-O exf4
11. Bxf4 f6
12. Rad1 Ke8
13. e5 fxe5
14. Bg3 Nc5
15. Bxe5 Bxe5
16. Nxe5 Be6
17. b4 Ncd7
18. Nf3 Ke7
19. Ng5 Nf8
20. Nxe6 Nxe6
21. Bg4 Nd7
22. Rde1 Ndf8
23. Ne4 Nd8
24. Nc5 Kd6
25. Rf6 Kc7
26. Re7 Kb8

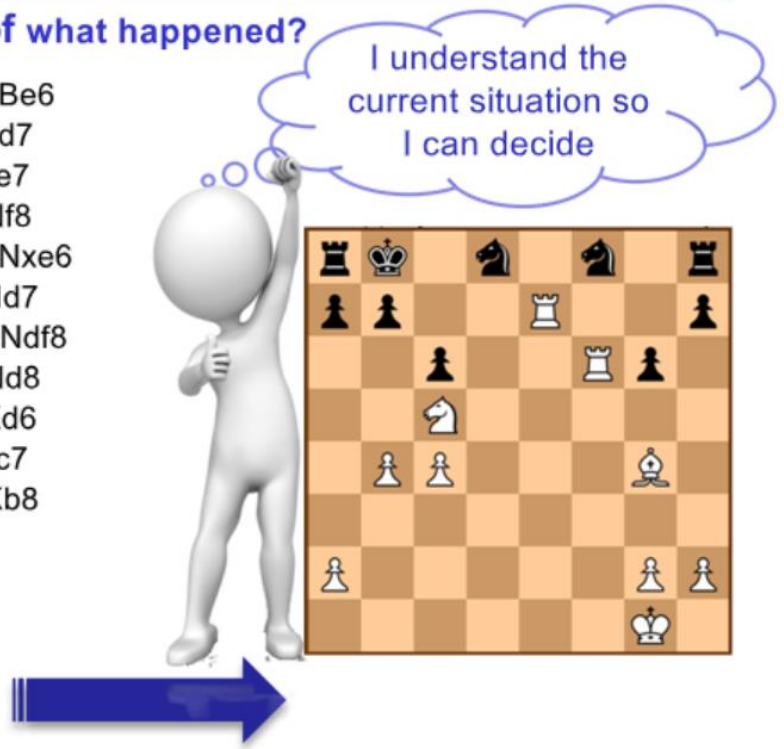

Linguistic beauty

Formal description

SNOMED CT is

Not Just a Code System

- Concept
  - Unique clinical idea
- Description
  - Synonyms
- Polyhierarchy
- Attribute relationships
  - Cross-linking concepts
  - Concept model

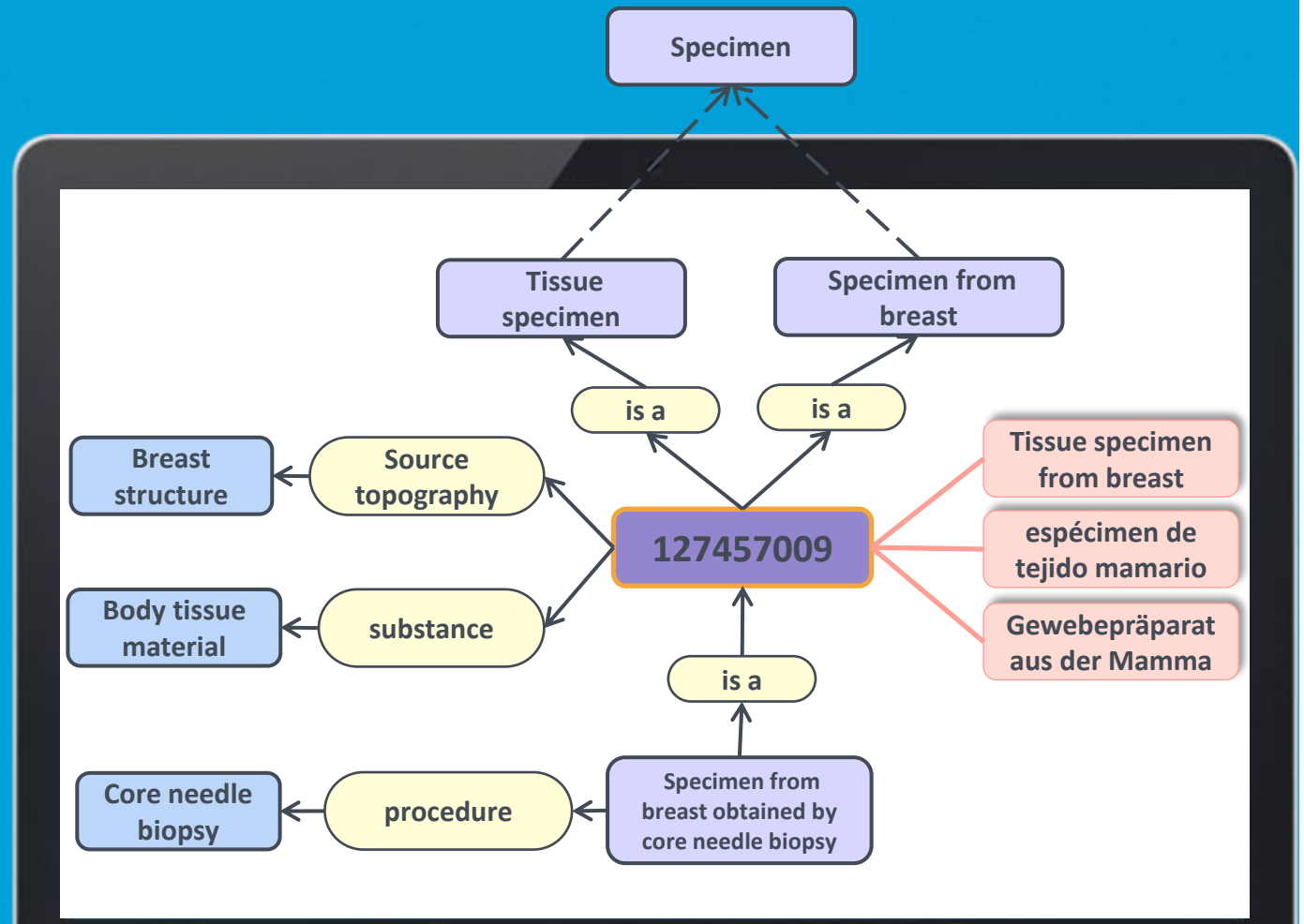

SNOMED International

Concept model

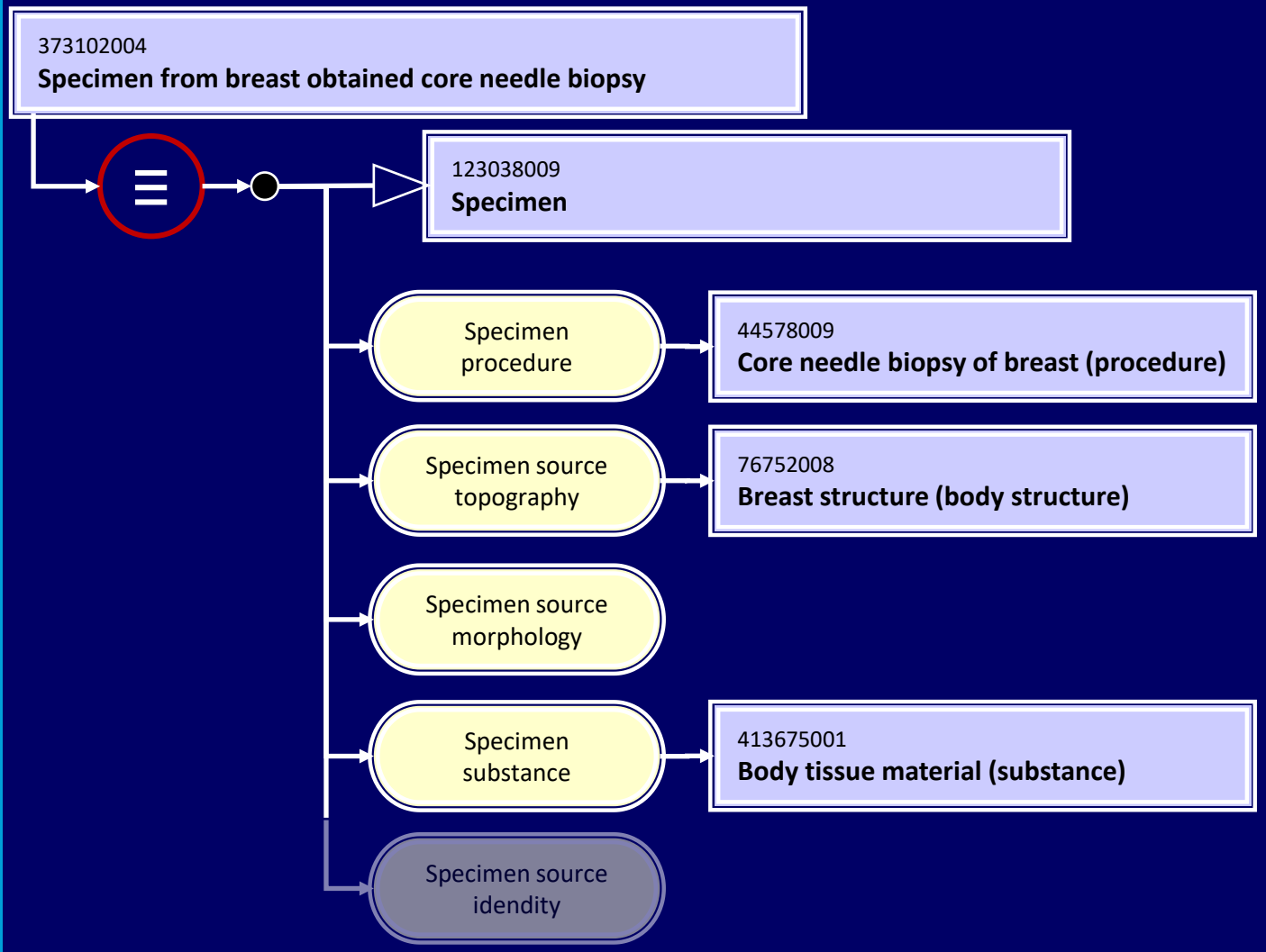

Concept model defines

- Valid attributes
- Attribute range

Equivalence of

- precoordinated concept
- And expression

Postcoordination

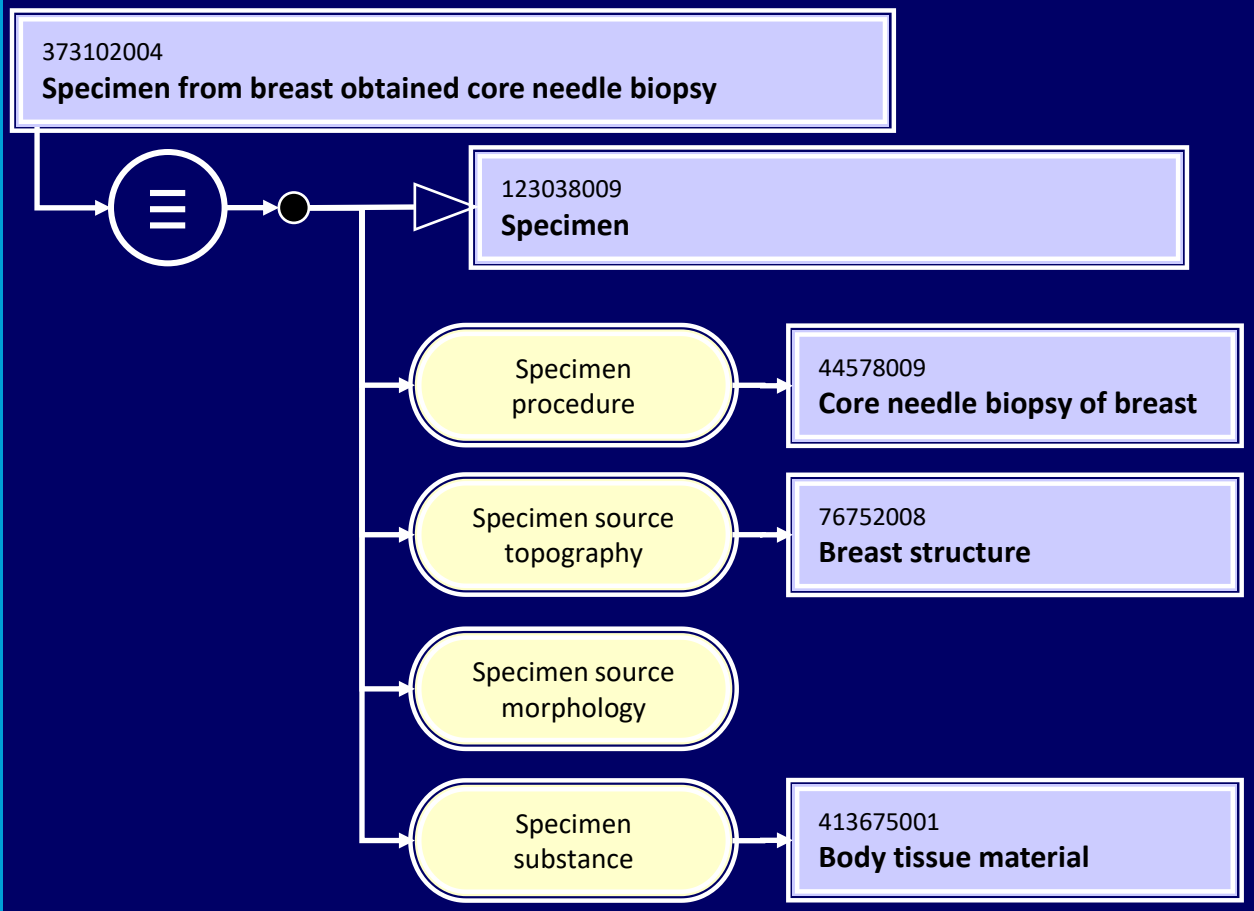

sibling

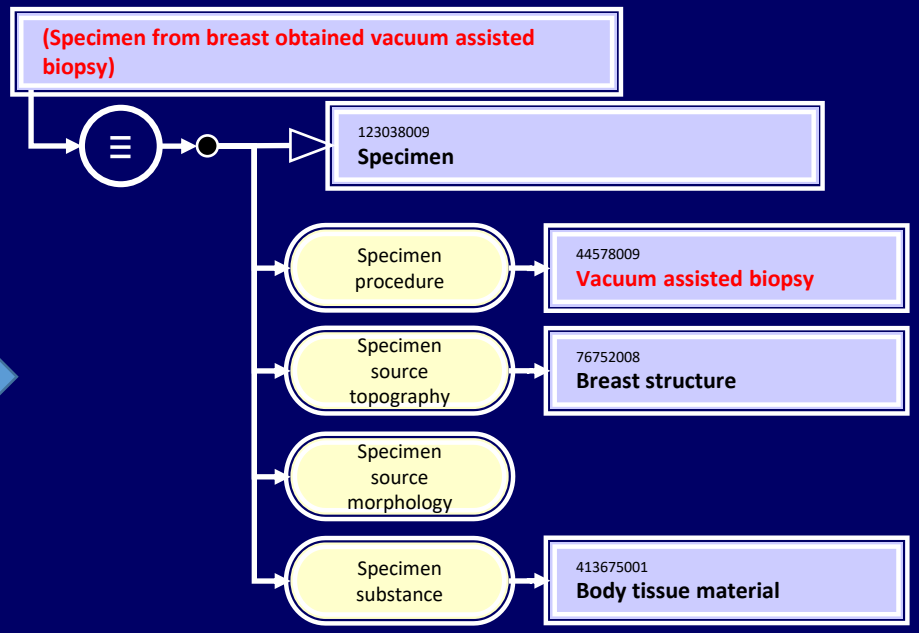

descendant

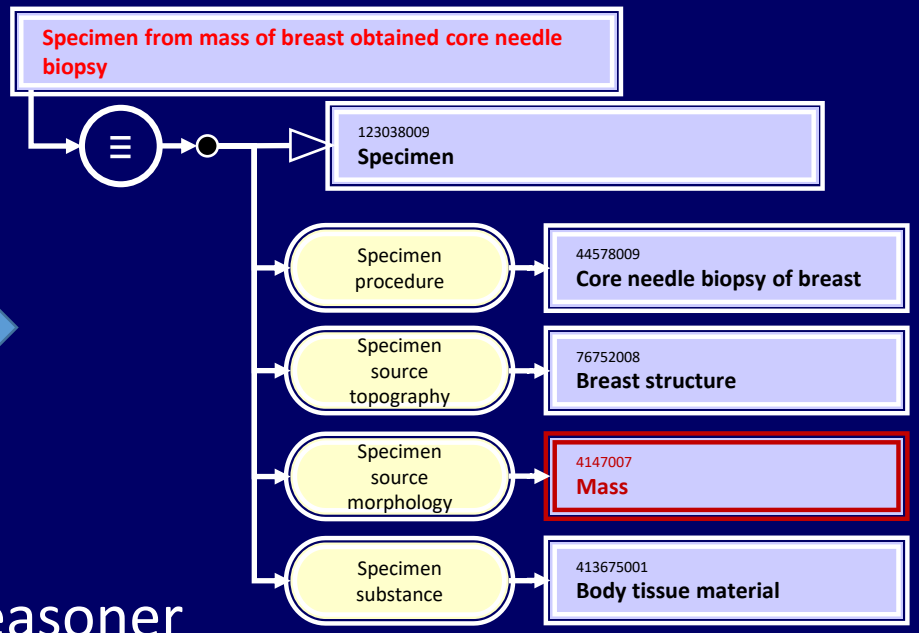

Terminology server - Description logic reasoner

Medizininformatikinitiative - Pathologiebefundbericht

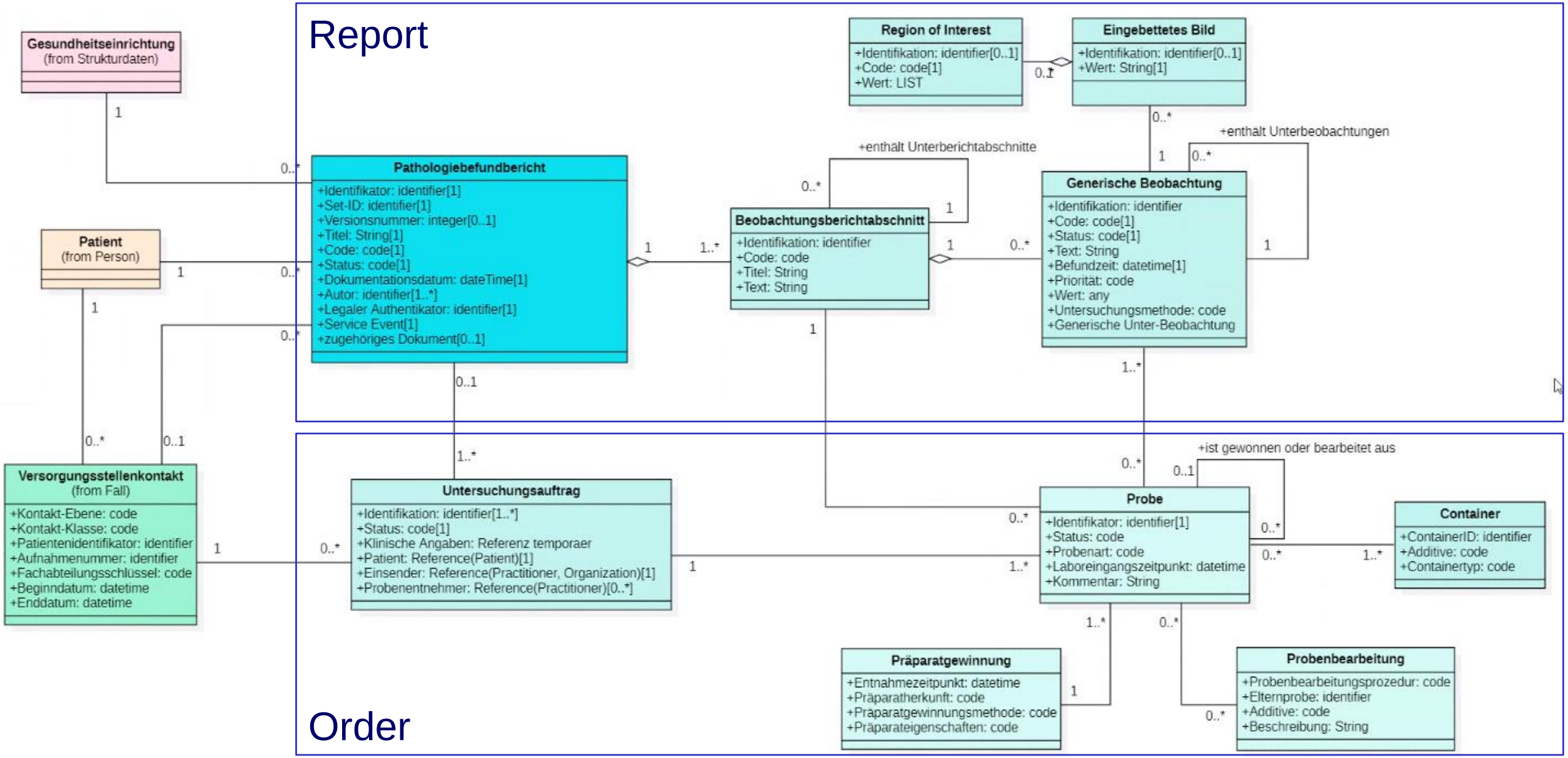

Order

373102004
|Specimen from breast obtained by image guided core biopsy|

Pathology

Report

408643008 |Infiltrating duct carcinoma of breast (disorder)|
: 372276001 |Nottingham Combined Grade (observable entity)| = 369791003 |Nottingham Combined Grade II: 6-7 points (finding)|,

Order: Snomed CT Concept Model - Specimen

373102004
Specimen from breast obtained by image guided core biopsy

Order

123038009
Specimen

Specimen procedure → 44578009 **Core needle biopsy of breast**

Specimen source topography → 76752008 **Breast structure**

Specimen source morphology

Specimen substance → 413675001 **Body tissue material**

Workflow

Macroscopy
Grossing scheme

Implicit clinical question
Standard histological procedures

Clinical findings
Explicit questions
Standard histological procedures

Histology
Cytology

Grossing perspective

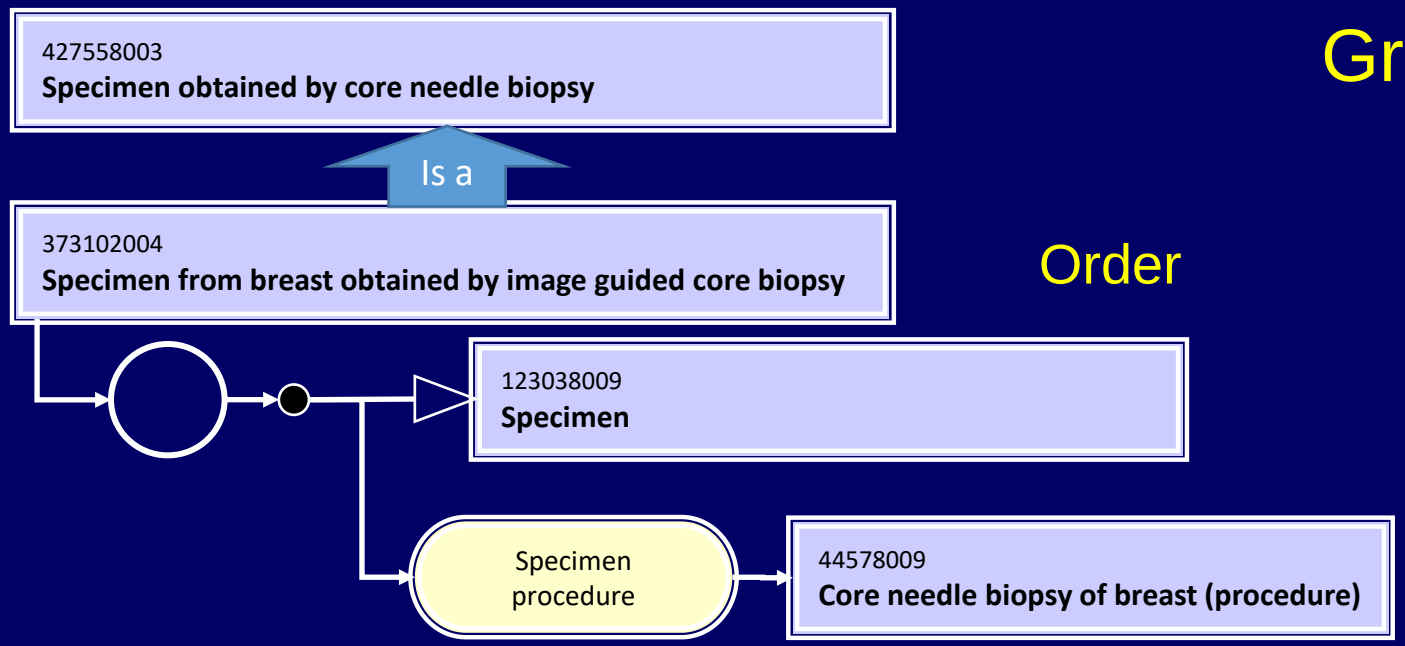

Order → Workflow

Macroscopy
Rule for all core needle biopsies

Description requirements (Observables)

399482008 |Total number of tissue cores|
371476002 |Specimen size, dimension 1|
371477006 |Specimen size, dimension 2|
397191008 |Specimen integrity|

Diagnostic perspective

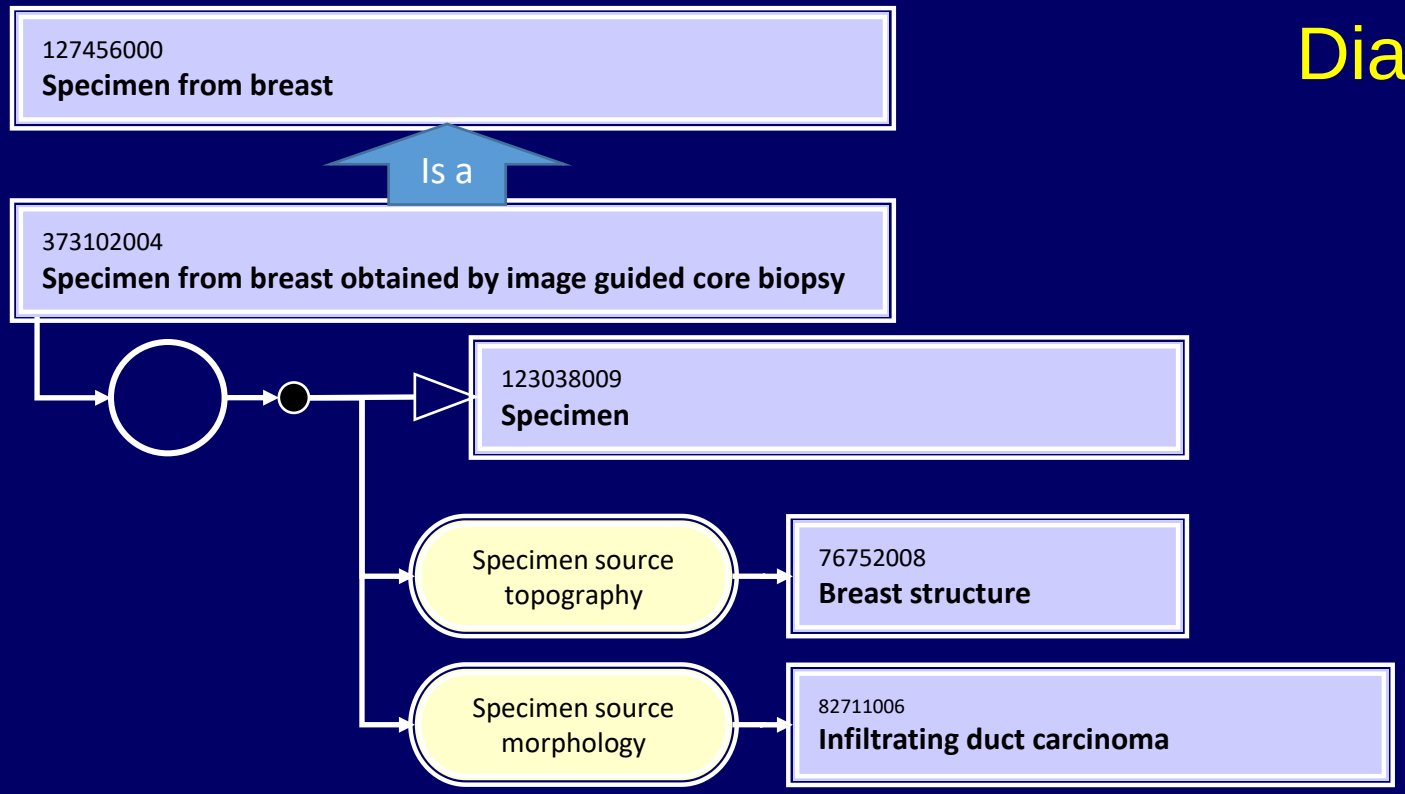

<< 79604008 |Disorder of breast| . 116676008 |Associated morphology|

Concept	Id
Adenoma of the nipple	65787003
Aggressive fibromatosis	47284001
Angiosarcoma	863926008
Apocrine metaplasia	81274009
Atrophy	13331008
Atypical hyperplasia	32416003
Atypical lobular hyperplasia	33889003
Benign fibroadenoma	1156873009
Benign papilloma	1157073002
Benign phyllodes tumour	16566002
Benign tubular adenoma	1156654007
Borderline phyllodes tumour	71232009
Breast implant-associated anaplastic large cell lymphoma	1172730009
Carcinoma	1187425009
Carcinoma in situ	1187138006
Carcinoma of salivary gland type	384951004
Carcinoma, metastatic	79282002
Chronic inflammation	84499006
Chronic lymphocytic inflammation	54727009
Columnar cell atypia	55465005
Comedocarcinoma, noninfiltrating	78197004
Cyst	367643001
Ductal carcinoma in situ, solid type	128880009
Dysplasia	25723000
Encapsulated papillary carcinoma	703545003
Fat necrosis	79682009
Fibrosing adenosis	50916005
Giant fibroadenoma	34882000
Granulomatous inflammation	6266001
Infiltrating carcinoma with ductal and lobular features	444057000
Infiltrating duct carcinoma	82711006

Select form (standardized reporting)
Filter or validate disorders

ICD-10

- C50.9 ???

Postcoordinated order

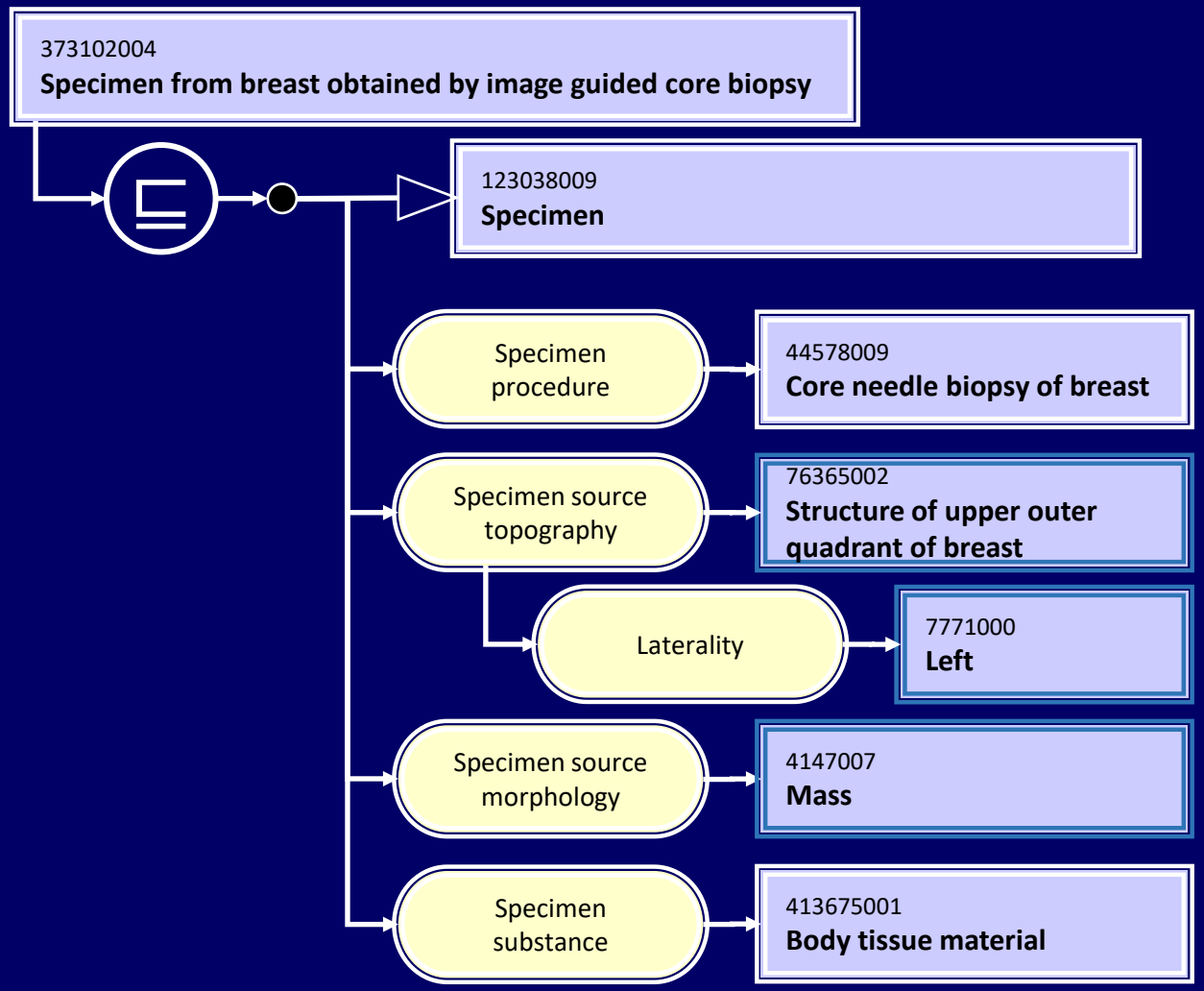

Order entry interface

- Core needle biopsy of breast
  - Ultrasound guidance
- Vacuum assisted biopsy of lesion of breast
  - Mammography imaging guidance
  - Magnetic resonance imaging guidance

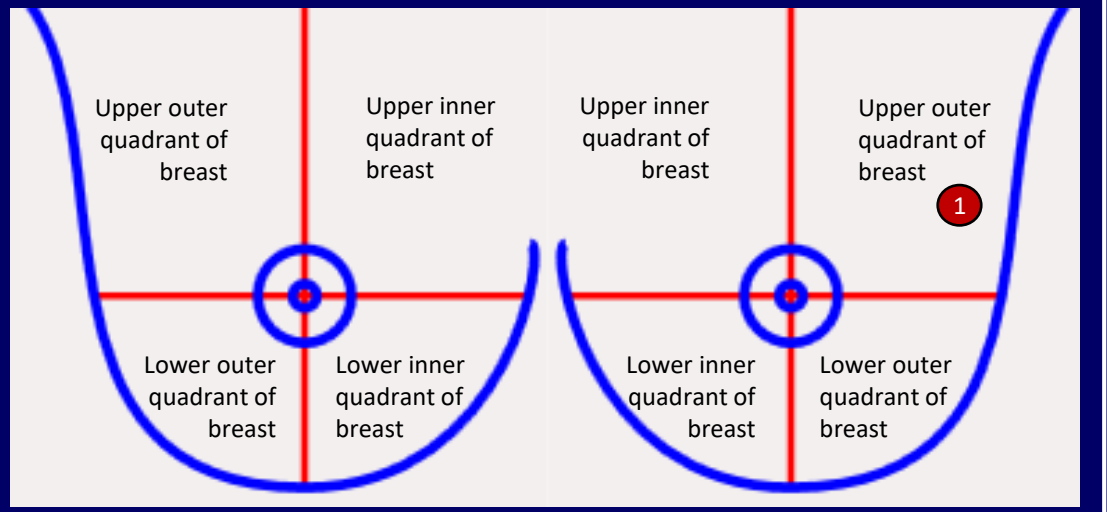

- Palpable mass
- Mammographic microcalcification of breast
- Mammographic architectural distortion of breast

5 x 2 x 5 x 3 = 150 permutations

Snomed CT Concept Model Specimen and Disorder

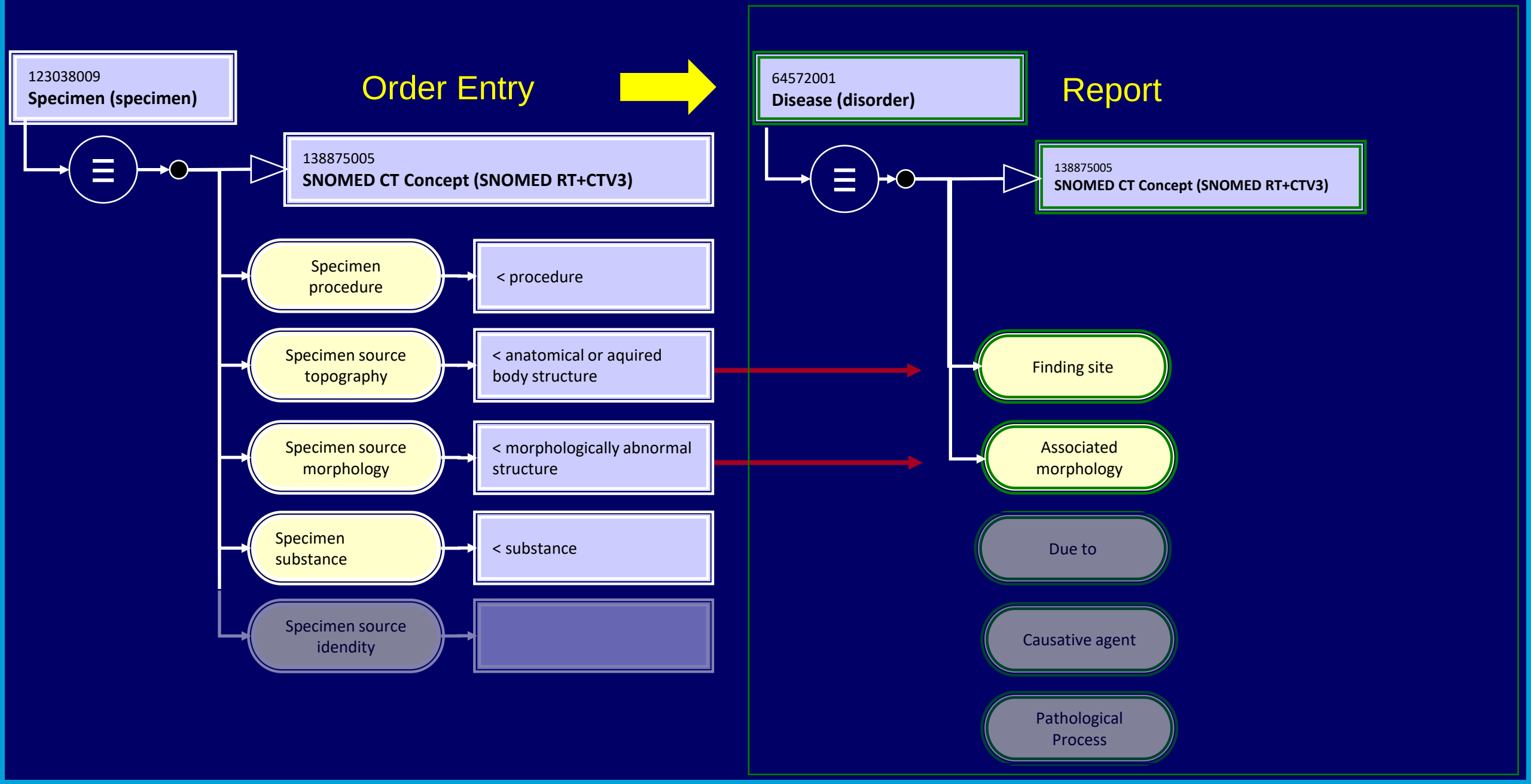

Transition: Specimen → Disorder

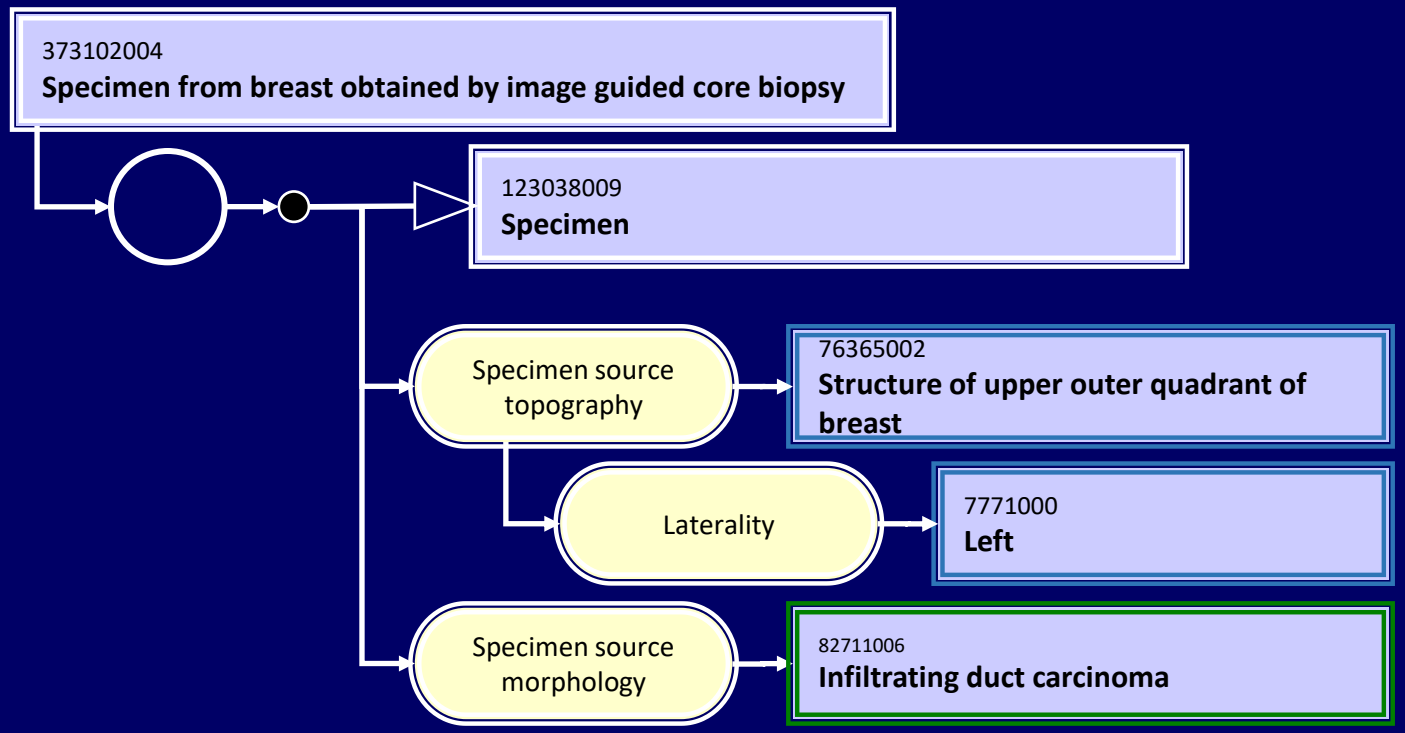

Transition: Specimen → Disorder

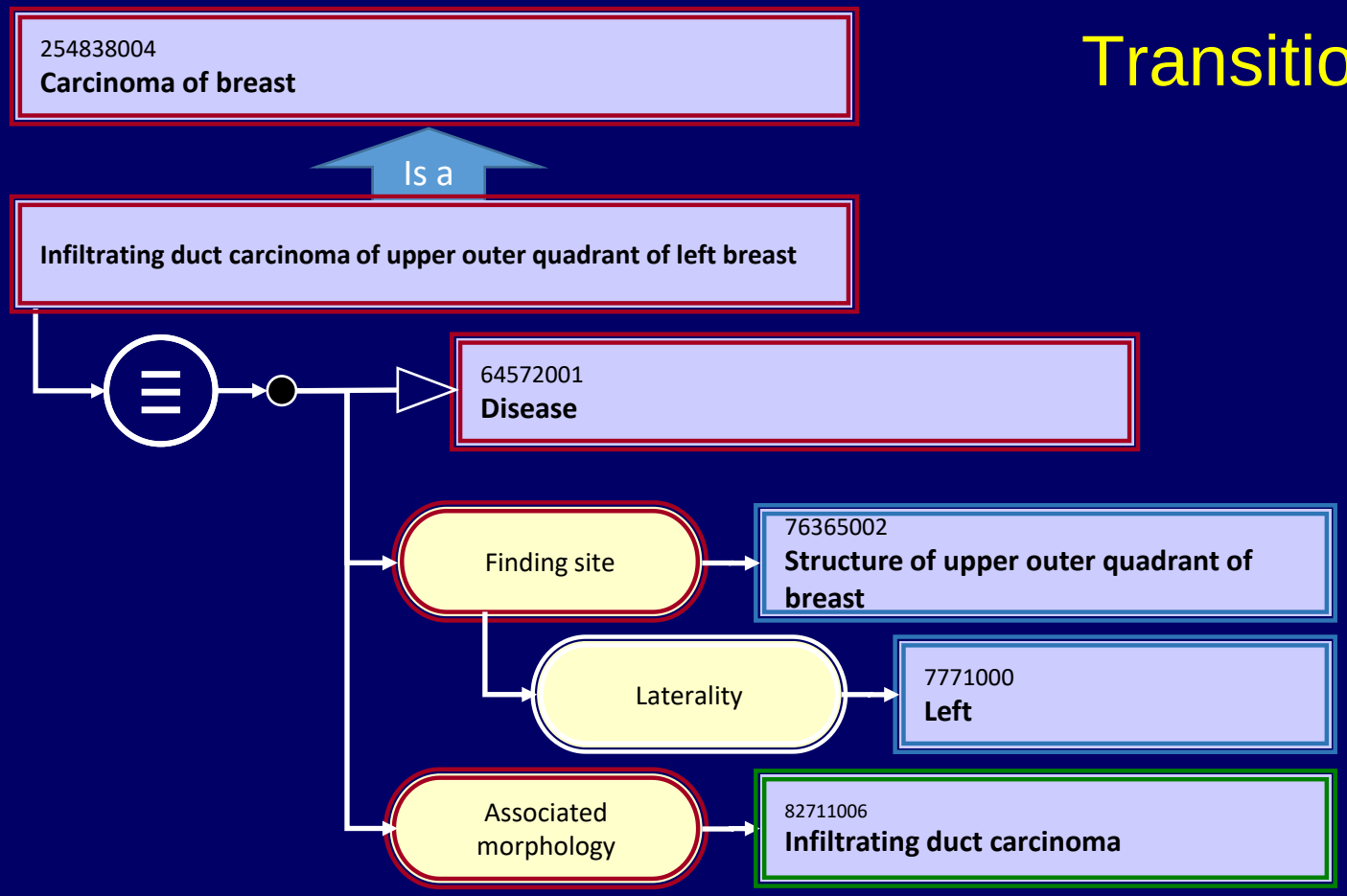

SNOMED CT to ICD-10 map
C50.4L

SNOMED CT to ICD-O simple map
8500/3

Guidelines

254838004
Carcinoma of breast

Mandatory observables
- Nottingham combined grade
- Intrinsic subtype
- B-Classification

Laboratory tests for intrinsic subtype
- Estrogen receptor
- Progesterone receptor
- Her2
- Ki67

Nottingham combined grade

	1	2	3
Tubular growth	>75%	10-75%	<10%
Pleomorphism	Small regular tumor cells	Some Pleomorphism	Marked Pleomorphism
	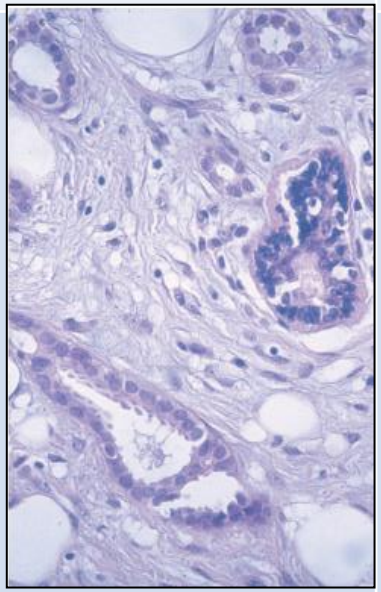	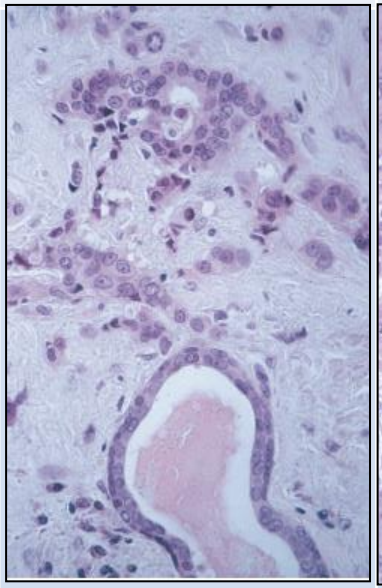	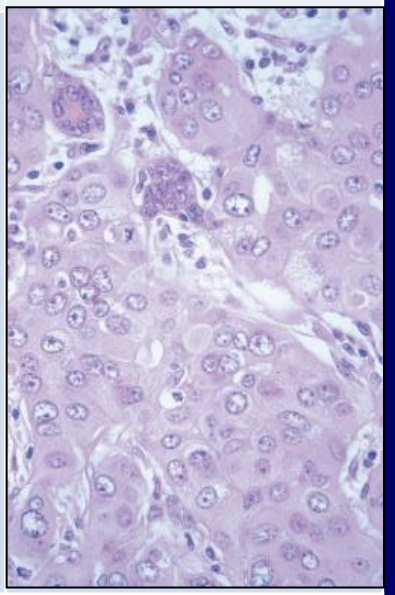
Mitoses / 10 hpf	12	22	

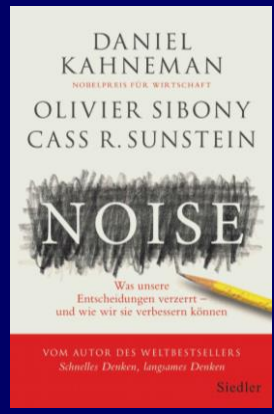

Report

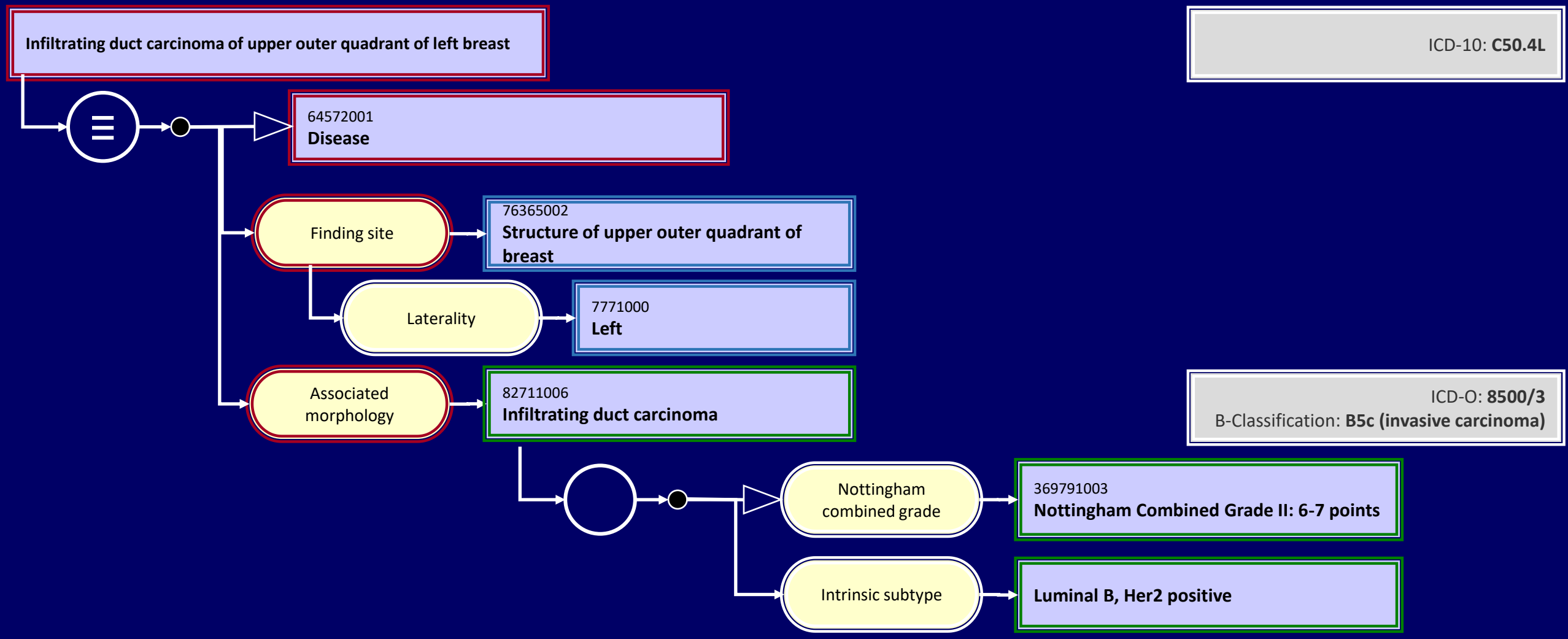

Mammastanzbiopsat (Oberer äußerer Quadrant – links) mit einem mäßig differenzierten duktal-invasiven Mammakarzinom.
Intrinsischer Subtyp: Luminal B, Her2 positiv.
B-Klassifikation: B5c (invasives Karzinom)

SNOMED CT is
Suitable for documentation

- Granularity / Postcoordination
  - Primary documentation
  - Reporting
- Polyhierarchy / Attribute Relationships
  - Different abstractions
  - Workflow
- Description logic / Classifier
  - Implementation
- Descriptions
  - Transfer into report
  - Translation

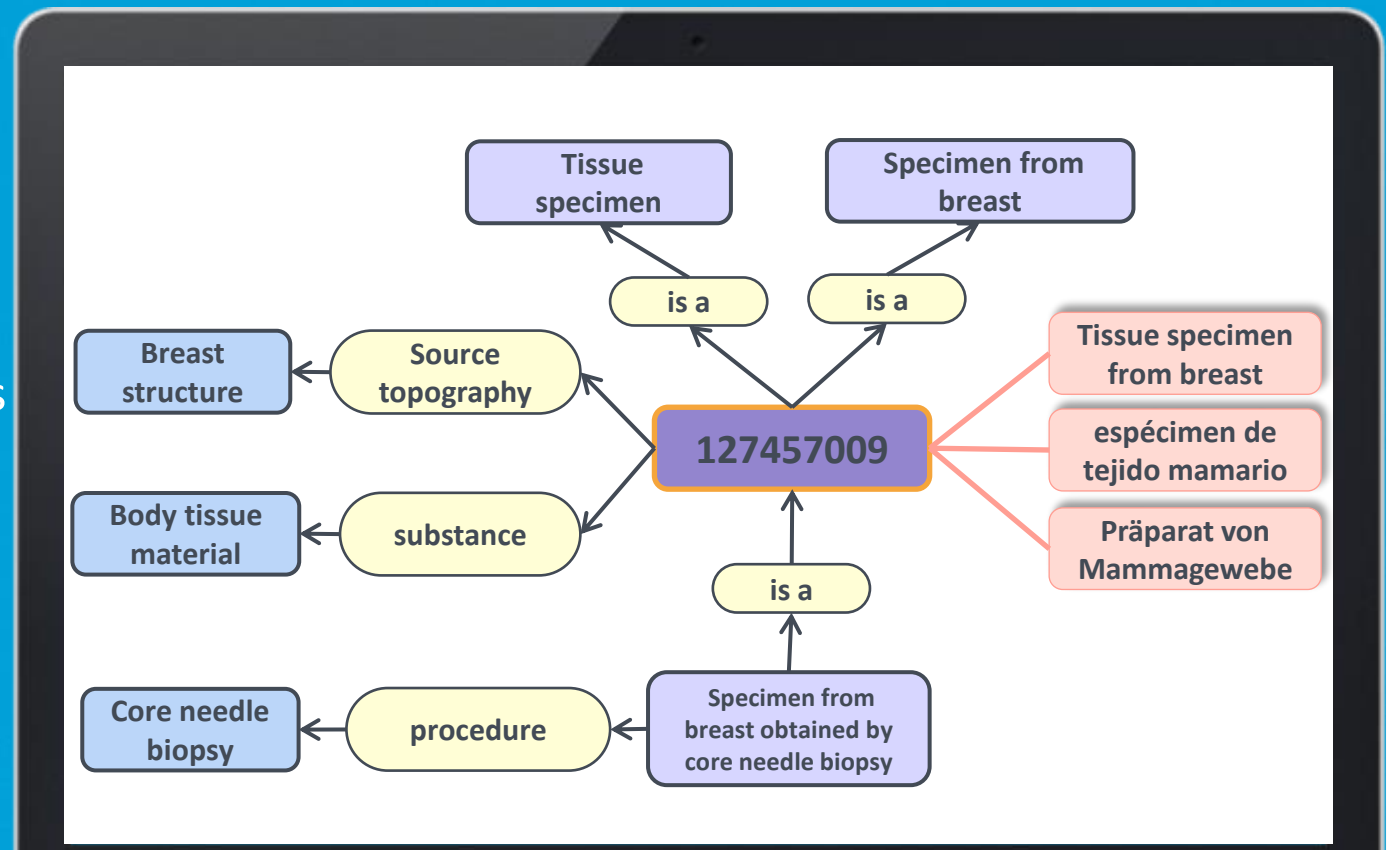

Postcoordination

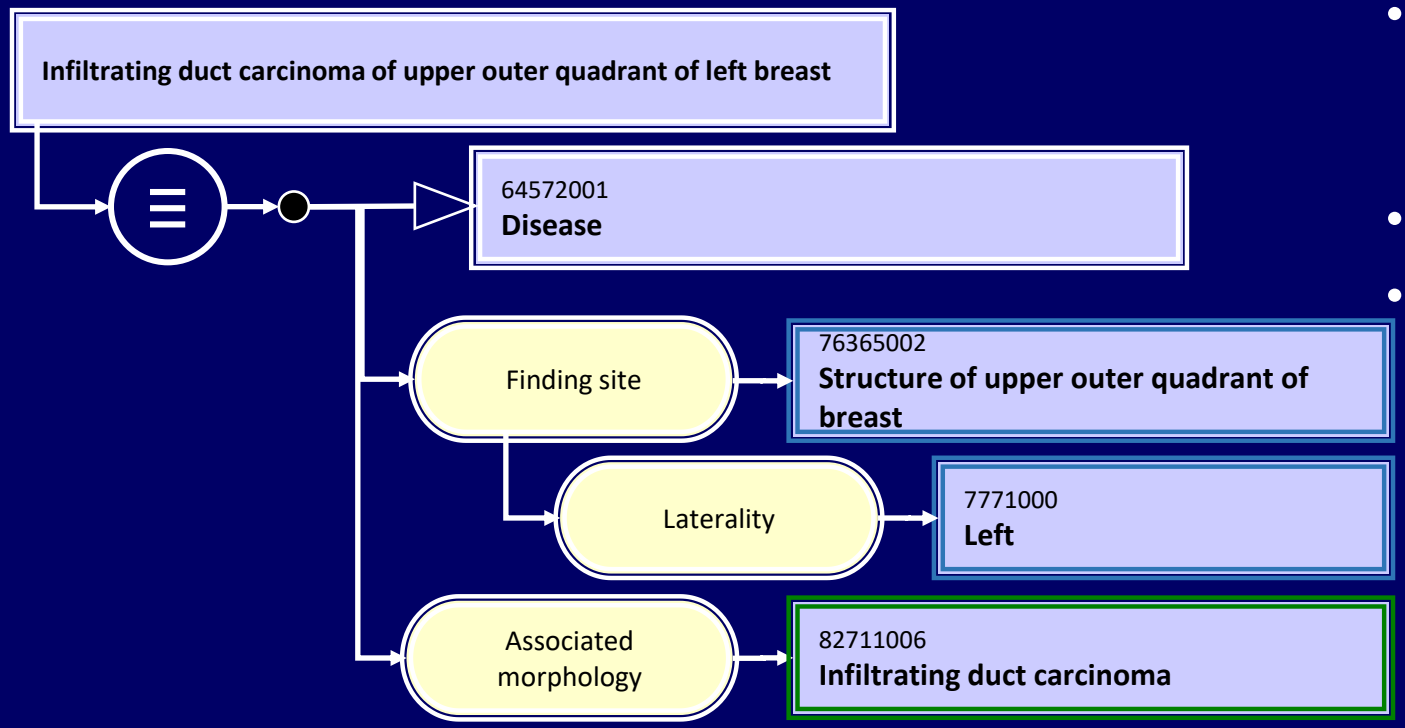

- Different aspects of the final clinical statement may be contributed by different specialities
- Reduces length of lists
- Precoordinated concepts are not flexible for primary documentation

Structured workflow – a promise for efficency and data quality

Chances

- More useful reports with less ressources
- Order information guides workflow
  - Validation of input
  - Calculation of derived values
- Medical history display
  - Based on disorders not time

Work ahead

- Snomed CT
  - Selection of concepts to avoid excessive precoordination
  - Definition of missing concepts
  - Computable specimen description
  - Translation
  - Terminology services
    - Postcoordination
- Reporting requirements
  - ICCR
    - Snomed terms currently beeing modelled
  - Guidelines
  - Non-malignant conditions
- Graphical elements
- Dealing with uncertainty